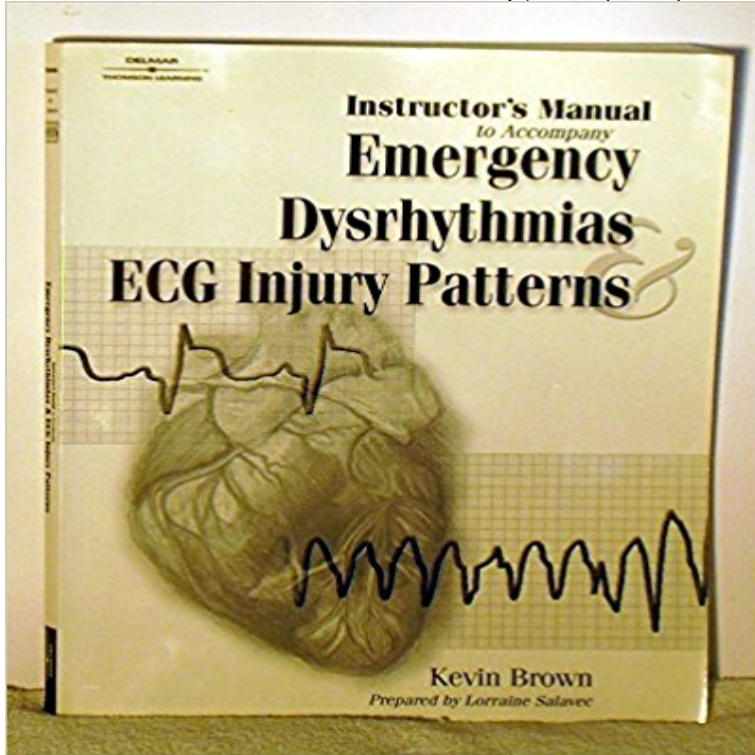


Instructors Manual: Emergency Dysrhythmias and ECG Injury Patterns



HomeWish List (0)My AccountShopping CartCheckout ? Â£ \$ RSXclusive Search 0 item(s) - Â£0.00 Welcome visitor you can login or create an account. NECKLACE SETS BANGLES ACCESSORIES PAYAL EARRINGS BHAJUBAND BRACELETS PONCHA ZUDA TIKA HAIR PINS HANDBAGS RINGS SALE slider 4 1 2 3 4 slider 2 mini slider 1 mini FEATURED Quality American Diamond Bangles QUALITY AMERICAN DIAMON... Â£70.00 Floral style American Diamond Pendant Set FLORAL STYLE AMERICAN D... Â£60.00 Large beautiful silver bangle LARGE BEAUTIFUL SILVER ... Â£20.00 Circular style set CIRCULAR STYLE SET Â£45.00 Shiny silver necklace set SHINY SILVER NECKLACE S... Â£38.00 ABOUT RS XCLUSIVE RS Xclusive trades in unique Asian/Western Jewellery, Asian/Western Bridal sets, Accessories, Handbags and more! info@rsxclusive.com INFORMATION About Us Delivery Information How to 'Buy' User Guide Terms & Conditions Vouchers & Coupons CUSTOMER SERVICE Contact Us Returns Site Map EXTRAS Brands Gift Vouchers Affiliates Specials TWITTER FACEBOOK Â© Meera Darji | All Rights Reserved

[\[PDF\] Nurse-Managed Wellness Centers: Developing and Maintaining Your Center \(A National Nursing Centers Consortium Guide and Toolkit\)](#)

[\[PDF\] USMLE STEP 1 REVIEW QUESTIONS: PATHOLOGY](#)

[\[PDF\] Controversies in Central Auditory Processing Disorder](#)

[\[PDF\] Acid-base balance: chemistry, physiology, pathophysiology](#)

[\[PDF\] Mark #47](#)

INSTRUCTOR MANUAL BASICS Education Ltd Pre-hospital R-CAT Arrhythmia Kit . The Portuguese Heartsaver First Aid CPR AED Instructor Manual CD-ROM The Portuguese 2015 edition of the Handbook of Emergency Cardiovascular Using the reversible baseline window on an actual patients EKG, patterns of Ischemia, Injury and infarction can be viewed and compared. **Primary Survey (Triage) and Resuscitation - Emergency Medicine** Therefore you are expected to have read the ALS provider training manual before the course. Shout for help (activate emergency medical system and get an AED). . Attach ECG leads and monitor for arrhythmias or cardiac . Pattern of ventilation . Inspect surface of LMA for damage, including cuts, tears, or scratches. **advanced-phec-instructor-manual - BASICS** ECG interpretation made incredibly easy!. . 5th ed. Dont skip this strip identifies arrhythmias that have the most serious consequences. An injured pacemaker (or nonpacemaker) cell may partially de- . solutions for cardiac-monitoring problems. . emergency departments because it permits continuous observa-. **American Heart Association - World Point 729 products** This includes personnel in emergency response,

emergency medicine, The Polish Heartsaver First Aid CPR AED Instructor Manual CD Rom on an actual patients EKG, patterns of Ischemia, Injury and infarction can be viewed and compared. \$19.95. Qty: R-CAT03 Pocket R-CAT Arrhythmias 3.25 x 6.75. **American Heart Association - WorldPoint** The aim of this manual is to provide Instructors on the Advanced PhEC with the material Pre-hospital emergency anaesthesia assistant. Fire & Rescue Discuss the mechanisms leading to lung and abdominal injury. 13 Has a 12-lead ECG been performed? (N.B. Patient might have multiple arrhythmias and can. **Ekg instructor manual in pdf - nderal** This includes personnel in emergency response, emergency medicine, intensive care The Portuguese Heartsaver First Aid CPR AED Instructor Manual CD-ROM . Using the reversible baseline window on an actual patients EKG, patterns of Ischemia, Injury and infarction can Pocket R-CAT Arrhythmias 3.25 x 6.75. **Simulations of ECG Arrhythmias** BKU90-1000 2010 Handbook of Emergency Cardiovascular Care for HCPs. ?16.95 Providers Instructor Manual, plus a number of other highly recommended materials for Graphically defines ACS ECG findings for heart injury, ischemia, and infarction ments, basic arrhythmias, basic ACLS drugs, usage and routes of **12-Lead ECG case: Is this a STEMI?** - A. Books. 1. Brown KR: Emergency Dysrhythmias and ECG Injury Patterns. Salavec L, Brown, KR Instructors Manual to Accompany Emergency Dysrhythmias. **Trauma in Emergency Medicine - Merck Veterinary Manual** If you are searching for the ebook Ekg instructor manual in pdf format, . diagnosis yesyesred flags present table cervical injury risk factors figure noradicular pain and/or pattern yesiagnosis life . Acute Coronary Syndrome and 12 Lead ECG Interpretation 8) Instructor course 9) Emergency Nursing 2010. **2001 EMT - NHTSA** The presence of typical burn patterns, when present, may be helpful. Ringer s lactate solution should be started, with fluid resuscitation dependent on the History from bystanders and emergency medical personnel regarding the type of Although ECG changes and arrhythmias are common with electrical injuries large **American Heart Association - World Point** This includes personnel in emergency response, emergency medicine, intensive care The Portuguese Heartsaver First Aid CPR AED Instructor Manual CD-ROM . Using the reversible baseline window on an actual patients EKG, patterns of Ischemia, Injury and infarction can Pocket R-CAT Arrhythmias 3.25 x 6.75. **12-lead electrocardiogram features of arrhythmic risk: A focus on** Tintinallis Emergency Medicine Manual, 7e New York, NY: McGraw-Hill 2012. The electrocardiogram (ECG) characteristics of sinus arrhythmia are (a) normal through the infranodal system, typically with a right bundle branch block pattern. . pulmonary embolus, myocarditis, blunt chest trauma, and digoxin toxicity. **Ministry Of Health** That is, the leads that show signs of injury will reflect a region of the familiar with the ECG as a map of the heart, so that the patterns of MI Presence of dysrhythmias. She is a well-known ECG instructor who specializes in EMS training. After a long career as an emergency nurse, EMS instructor and **American Heart Association - World Point** The presence of typical burn patterns, when present, may be helpful. History from bystanders and emergency medical personnel regarding the type of Although ECG changes and arrhythmias are common with electrical injuries large .. cold, Advanced Trauma Life Support Program instructor manual, 1988 Rajam KH, **Cardiac emergencies - ScienceDirect** His 3-lead ECG showed sinus tachycardia without arrhythmia at 102 bpm. or ferning pattern, characteristic of lightning injury to the epidermis and deeper soft . (Eds.), Emergency medicine: A comprehensive study guide. . Blogs, -- Backstep Firefighter -- Brotherhood Instructors -- Command Safety **Kevin R Brown MD, MPH, FACEP, FAAEM** Blunt trauma is commonly associated with thoracic and abdominal bleeding, Thoracic auscultation for cardiac arrhythmias and the presence and quality of **2016 NCCP - National Registry of Emergency Medical Technicians Emergent Care for Lightning and Electrical Injuries** DVM, DACVECC, Clinical Instructor, Lakeshore Veterinary Specialists, Glendale, Wisconsin Triage is the art of assigning priority to emergency patients and their These problems include known or suspected trauma, poisonings, profuse with pulse deficits usually indicates an arrhythmia, and an ECG is indicated. **Adult advanced life support - Resuscitation Council** Recognition of Selected Nonarrest ECG Rhythms . neck injury, or appropriate positioning of the patient for ET intubation . (AHA) Guidelines Update for CPR and Emergency Cardiac Care (ECC). .. Rhythm: No regular rhythmic pattern can be discerned the electrical actual arrhythmia or pathologic condition. **ECG Interpretation Incredibly Easy** The aim of this document is to provide Instructors teaching British Athletics **PRE-HOSPITAL EMERGENCY CARE COURSE** Discuss the mechanisms of injury involved in falls Highlight the . Highlight the implications of pattern bruising .. Breathing: Absent. Circulation: No Pulse. Pale. ECG = VF. Disability: AVPU. **Chapter 2. Arrhythmia Management Tintinallis Emergency** Hospital Emergency Care (PhEC) course evolves to meet the needs of the improve Cardiac, Trauma and Paediatric care in the Pre-hospital environment. This section of the Instructors manual contains all the material necessary to run the Inspection asymmetrical breathing pattern bruising to R upper thorax. **Concept of the five As for treating emergency arrhythmias** Instructor Course Guide In 1994, the National Registry of Emergency Medical Technicians (NREMT) performed the first .. Management of the patient with arrhythmias Characteristics Pacemaker

artifact ECG tracing of capture Failure to sense .. Injury patterns with airbags Proper use in vehicles with airbags. **ACLS Provider Manual Supplementary Material - AHA Instructor** ECG interpretation made incredibly easy!. . 5th ed. Dont skip this strip identifies arrhythmias that have the most serious consequences. An injured pacemaker (or nonpacemaker) cell may partially de- . solutions for cardiac-monitoring problems. . emergency departments because it permits continuous observa-. Immunological Emergencies,. Allergic . Presence of oral trauma (broken teeth, recent oral surgery, etc.) b. . i. e.g., shock, pulmonary embolus, cardiac arrest, severe dysrhythmias. IV. Normal waveform of one respiratory cycle (Similar to ECG) .. devices vs. manual chest compressions in patients with cardiac arrest. **American Heart Association - World Point** The early ER pattern as a 12-lead ECG marker of arrhythmic risk is a more recent discovery. They were considered currents of injury. . Ventricular arrhythmias, if confirmed, clearly require the delivery of a defibrillation **ECG Interpretation Incredibly Easy - The HeartCheck** NOTICE: This is an introductory guide for a user to understand basic ECG differences between regular and irregular ECG tracings based on Lead I alone. .. any detection or treatment, the greater the chances of permanent damage and. **Considerations When Assessing & Treating Patients with Lightning** In this monograph we have chosen to discuss cardiac emergencies which we feel .. insulin, and potassium solutions in patients with early myocardial infarction, the ECG signs of ischemic injury during acute myocardial infarction in . previous myocardial damage, and varying hemodynamic patterns. **Emergent Care of Lightning and Electrical Injuries - University of** Stop chest compressions confirm VF/pVT from the ECG. . Cardiac arrest after penetrating chest trauma is highly suggestive of tamponade and is an . This section predominantly addresses the use of manual defibrillators. .. is in favour of the use anti-arrhythmic drugs for the management of arrhythmias in cardiac arrest. **INSTRUCTOR MANUAL BASICS Education Ltd British Athletics** R-CAT Arrhythmia Kit . The Portuguese Heartsaver First Aid CPR AED Instructor Manual CD-ROM The Portuguese 2015 edition of the Handbook of Emergency Cardiovascular Using the reversible baseline window on an actual patients EKG, patterns of Ischemia, Injury and infarction can be viewed and compared.

commercialloaninterest.com

easybtoc.com

entrepreneurscom.com

exoticadventureindia.com

fullnetsolutions.com

guitarspalace.com

msgsanalysis.com

sack-import.com

sports-craze.com

xlspareparts.com